

INI CET Radiology Answer Key 2024

Q 1. Which of the following statement is true concerning computed tomography?

- A. An unfiltered x-ray beam is used.
- B. 1st investigation in a suspected Gall stone is CT scan
- C. A CT number of 0 is assigned to water
- D. The typical effective dose for a CT head scan is 20 mSv.

Ans: (c)

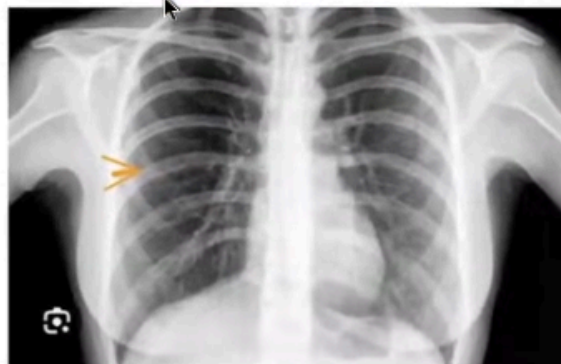
Q 2. Which of the following contrast agent can be safely administered in a kidney disease patient without the need of monitoring renal function?

- A. Gadolinium
- B. Iodinated ionic Contrast
- C. Iodinated non ionic Contrast
- D. USG contrast

Ans: (d)

Q 3. Identify the marked Structure-

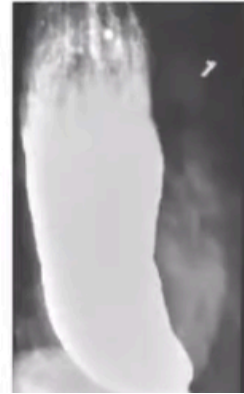
- A. Anterior end of Rib
- B. Posterior end of Rib
- C. Right Pulmonary artery
- D. Costal Cartilage



Ans: (d)

Q 4. A 26 year old patient presented with weight loss & halitosis. Barium swallow is given. What is the likely diagnosis?

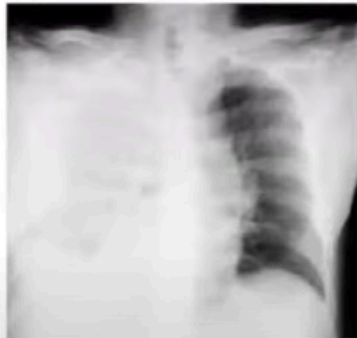
- A. Ca esophagus
- B. Achlasia Achardia
- C. ?
- D. ?



Ans: (b)

Q 5. A 26 year has a stab injury and now presented to casualty with following Chest X-ray. Probable diagnosis?

- A. Hemothorax
- B. Pneumothorax
- C. Pulmonary Contusion
- D. ?



Ans: (a)