

INI CET 2024 Surgery Answer Key Unofficial

Q. Which of the following is/are the complications associated with GERD?

1. Asthma
2. Laryngitis
3. Pulmonary Fibrosis
4. Chronic cough

- a. 1,2
- b. 1,2,4
- c. 1,2,3
- d. 1,2,3,4

Ans: (d)

Q. Which of the following is the most common hernia in females?

- a. Direct Inguinal hernia
- b. Indirect inguinal hernia
- c. Femoral hernia
- d. Obturator hernia

Ans: (b)

Q. Which of the following is not a marker of GIST?

- a. SDH
- b. C-kit
- c. PDGF
- d. Nestin

Ans: (d)

Q. ER positivity is used as which of the following in the context of breast carcinoma?

- a. Diagnostic marker
- b. Prognostic marker
- c. Surrogate molecular marker
- d. Treatment

Ans: (b)

Q. All of the following statements regarding Wilms tumor is true, except?

- a. Presents as an abdominal mass
- b. Most commonly seen <5yrs of age
- c. Majority patients recover due to chemotherapy and radiotherapy
- d. Lung metastasis is rare and occurs late

Ans: (a) & (b)

Q. The given instrument is used for which of the following procedure?

- a. PEG
- b. Central line
- c. Orogastric tube insertion
- d. ICD



Ans: (a)

Q. 45-year-old female presents with recurrent episodes of right flank pain, hematuria, and a history of urinary tract infections. Urine analysis shows alkaline urine with a pH of 8.0. Which of the following is the most likely underlying cause of this patient's condition?

- a. Triple phosphate stone
- b. Ca Oxalate Stones
- c. Uric Acid Stones
- d. Cystine Stones



Ans: (d)

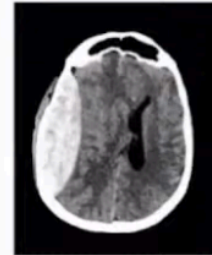
Q. A 52-year-old patient diagnosed with invasive ductal carcinoma in situ presents with ulceration on skin and inflammatory signs. Nipple retraction was also present. This patient is classified under which stage?

- a. Stage 3
- b. Stage 4 with node positivity
- c. T4b
- d. No metastasis

Ans: (a) & ©

Q. A 35-year-old male sustained a head injury following a motorcycle accident. He experienced a brief loss of consciousness at the scene. Upon regaining consciousness, he developed severe headache and began to feel drowsy. A CT scan of the head is performed. Which of the following should be the management for this patient?

- a. Anticoagulants
- b. Immediate surgery
- c. Observation in ICU
- d. Mannitol to reduce ICP



Ans: (b)

Q. A 45-year-old patient presents to the clinic with complaints of food regurgitation and weight loss over the past several months. A barium swallow test is performed. what is the diagnosis?

- a. Achalasia cardia
- b. Esophageal carcinoma
- c. Zenker's diverticulum
- d. Diffuse esophageal spasm



Ans: (a)

Q. A 55-year-old male patient presents to the clinic with left lower lip weakness following a recent parotid gland surgery. Considering the surgical history and current symptoms, what is the most likely site of the lesion causing this patient's condition?

- a. Main trunk of facial nerve
- b. Temporal branch of facial nerve
- c. Cervical branch of facial nerve
- d. Parotid duct

Ans: (a)

Q. Which of the following is not a risk factor for cholangiocarcinoma?

- a. Hepatitis B
- b. PCS
- c. Caroli's disease
- d. Opisthorchis viverrini

Ans: PBC

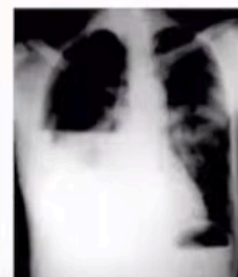
Q. Which of the following is not done in primary survey of trauma? (multiple choice)

- a. NCCT head
- b. CXR
- c. Intubation
- d. ICD drainage

Ans: (a)

Q. A 32-year-old male presents to the emergency department after sustaining a stab wound to the left side of his chest. He is in acute distress, with a heart rate of 120 beats per minute, blood pressure of 90/60 mmHg, and respiratory rate of 28 breaths per minute. On physical examination, there is decreased breath sounds on the right side. A chest X-ray is shown below. What is the diagnosis?

- a. Pneumothorax
- b. Hemothorax
- c. Tension Pneumothorax
- d. Hydrothorax



Ans: (b)

Q. Which of the following will not result in hoarseness of voice after a thyroid surgery?

- a. Dissecting/retracting strap muscles
- b. Exploring bearh's triangle
- c. Tubercle of zuckerand dissection
- d. Ligating superior thyroid vessels

Ans: (d)

Q. Mount fiju sign on CT is seen in which of the following?

- a. Pneumocephalus
- b. Pneumoperitoneum
- c. Pneumomediastinum
- d. Pneumothorax

Ans: (a)

Q. A 20-year-old chronic alcoholic presents with severe hematemesis . USG shows distention of the portal vein and the liver appears hyperechoic. Pantoprazole has been initiated. What is the next appropriate step in management?

- a. Initiate a course of broad-spectrum antibiotics
- b. Order a liver biopsy to assess for fibrosis
- c. Administer intravenous fluids and electrolyte replacement
- d. Perform an endoscopy to look for varices

Ans: (c)